

## Case Report

# A case of severe hyperkalaemia presenting with cardiac arrhythmias: An uncommon initial manifestation of chronic kidney disease

D H Sudusinghe<sup>1</sup>, J Indrakumar<sup>2</sup>

<sup>1</sup>Department of Physiology, Faculty of Medical Sciences, University of Sri Jayewardenepura, <sup>2</sup> Department of Medicine, Faculty of Medical Sciences, University of Sri Jayewardenepura

Corresponding Author: D H Sudusinghe, E-mail<dinesha94@yahoo.com>  
Received: January 2015, Accepted revised version: March 2015, Published: May 2015  
Competing Interests: Authors have declared that no competing interests exist.

**Key words:** hyperkalaemia, chronic kidney disease, arrhythmia

## Introduction

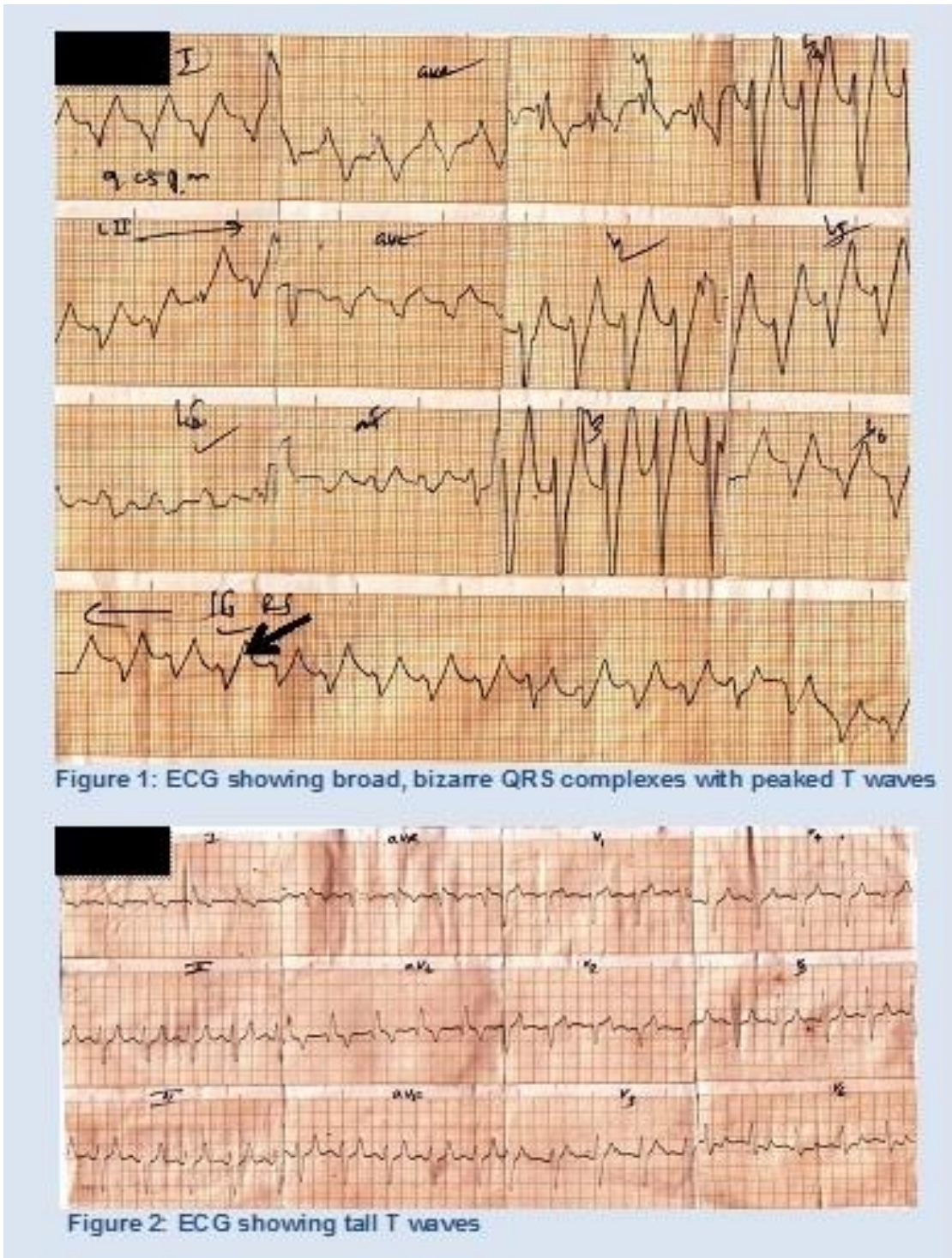
Hyperkalaemia is a potentially fatal condition. The relationship between potassium ( $K^+$ ) level and symptoms may not be consistent, as patients with longstanding hyperkalaemia may be asymptomatic in spite of high  $K^+$  levels<sup>1</sup>. The rapidity of change in  $K^+$  level influences the symptoms observed at any particular  $K^+$  concentration<sup>1</sup>. The most dangerous complication in patients with hyperkalaemia is cardiac arrhythmia. It is known that a  $K^+$  concentration greater than 10mmol/L is fatal, unless urgent treatment is instituted<sup>2,3</sup>. This report describes a patient presenting with a cardiac arrhythmia and extremely severe hyperkalaemia (9mmol/L) of uncertain duration, who subsequently recovered with medical management.

## Case history

A 56 year old male presented to hospital with shortness of breath, fever and reduced urine output of two days duration. He was on treatment with metformin and losartan for diabetes and hypertension.

On admission he was breathless with an oxygen saturation of 95 percent on room air and his blood pressure was 150/70mmHg. The cardiac monitor showed a broad complex tachycardia of 150 beats/min followed by nodal bradycardia. He was haemodynamically unstable during the episodes of bradycardia.

The electrocardiogram (ECG) showed tall T waves and broad QRS complexes (Figure 1) progressing to sine waves (arrow). His initial serum  $K^+$  level was repeatedly 9mmol/L and serum creatinine (SCr) was 682 $\mu$ mol/L. Urine microscopy showed 10-15 pus cells/HPF. Several ECGs were taken while the results of  $K^+$  concentration were awaited and all were compatible with severe hyperkalaemia (Figures 2, 3, 4). The results of his investigations are summarized in Table1.



The patient was treated with two doses of intravenous calcium gluconate along with two infusions of intravenous soluble insulin 10 units in 50ml of 50% dextrose within a period of 30 minutes. Subsequently, his cardiac rhythm reverted to sinus tachycardia with mild ST segment depression and T wave inversion in the lateral leads (Figure 5).

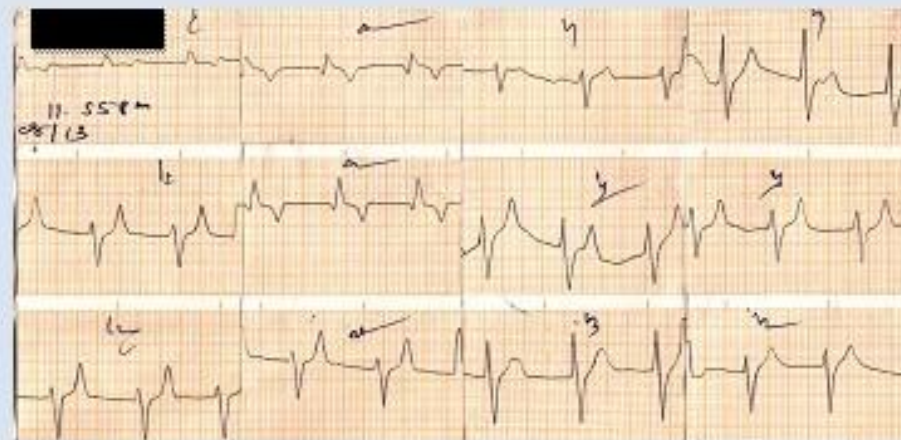


Figure 3: ECG showing tall T waves and intraventricular conduction delay

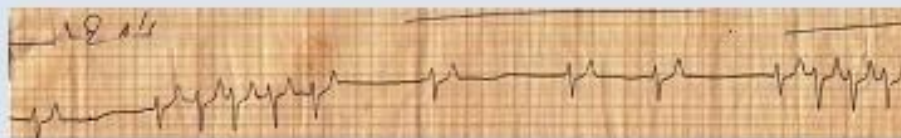

Figure 4: ECG showing episodes of tachycardia and nodal rhythm

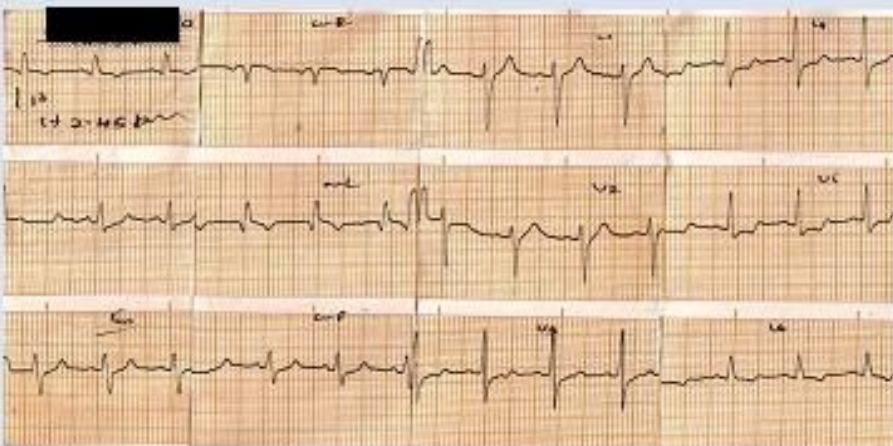


Figure 5: ECG after correction of hyperkalaemia

Although the serum  $K^+$  concentration improved with medical management, it remained high (6.5mmol/L) and he was commenced on hemodialysis. The patient was discharged on day eight and at one month review he remained clinically stable with a  $K^+$  level of 4.2 mmol/L and a SCr of 380 $\mu$ mol/L.

**Table 1: Summary of investigations – pre and post dialysis**

Investigation		Pre dialysis	Post dialysis
Full Blood Count	WBC	15.2 x 103/μL(N 85%)	
	Hb	15.4g/dL	
	PLT	293 x 103 /μL	
Serum Electrolytes	Na	128mmol/L	140mmol/L
	K	9mmol/L	4.9mmol/ L
Renal Function Tests	BU	34mmol/L	20mmol/ L
	SCr	682μmol/L	439μmol/ L
Urine Full Report	Pus cells	10-12/HPF	
	RBC	10/HPF	
Analysis of Blood Gas	pH	7.199	
	pCO2	23.6	
	pO2	87.7	
	HCO3	11.9	
	BE	-19	
	O2 sat	99%	
Ultra Sound scan of abdomen		Early renal parenchymal disease No evidence of obstructive uropathy	

## Discussion

Hyperkalaemia is a common complication of chronic kidney disease. Our patient's most recent SCr had been done two years ago and was within normal limits. He had been treated with losartan over a long period without being monitored for hyperkalaemia. The most likely explanation for our patient's severe hyperkalaemia was acute-on-chronic kidney disease precipitated by urinary sepsis with a possible contribution from losartan therapy.

It is known that hyperkalaemia can cause cardiac arrhythmias.<sup>1</sup> This report illustrates a case presenting with extremely severe hyperkalaemia as the first clinical manifestation of chronic kidney disease. The patient survived with medical management. A high index of suspicion of this potentially life-threatening complication should be maintained in high-risk patients. ECG is a readily available and convenient investigation to quickly diagnose hyperkalaemia, especially when severe. Hyperkalaemia should be suspected in any patient with chronic kidney disease with a new onset arrhythmia.

## References

1. Garth D. Hyperkalaemia in Emergency Medicine. <http://emedicine.medscape.com/article/766479-overview>
2. Tran HA. Extreme hyperkalaemia. *South Med J* 2005 Jul;98(7):729-32 <http://dx.doi.org/10.1097/01.SMJ.0000149407.51134.77>  
PMid:16108244

3. Hylander B. Survival of extreme hyperkalaemia. *Acta Med Scand.* 1987 Dec/Jan;221(1):121-3  
<http://dx.doi.org/10.1111/j.0954-6820.1987.tb01253.x>  
PMid:3565081
4. ECG features of hyperkalaemia - Life in the Fast Lane [lifeinthefastlane.com/ecg-library/basics/hyperkalaemia](http://lifeinthefastlane.com/ecg-library/basics/hyperkalaemia)
5. Palmer MD. Managing hyperkalaemia caused by inhibitors of the renin–angiotensin–aldosterone system. *N Eng J Med* 2004 Aug 5;351(6):585-592.  
<http://dx.doi.org/10.1056/NEJMra035279>  
PMid:15295051